ZIMMER BIOMET

Oxford Microplasty Instrumentation

CSAO Conference 46th Annual
September 13th-15th, 2015

Oxford Microplasty Instrumentation

Proven, safe and reproducible results

Topics

- Instrumentation
  - Set Overview
- Surgical Technique
  - Key Steps
    - Highlighting Key Instruments
    - Improvements vs Phase 3 technique

ZIMMER BIOMET

Instrumentation

Instrumentation Overview

Phase 1
1976 - 1988

- Problems with balancing due to femoral prep
- A lot of eyeballing

Phase 2
1988 - 1998

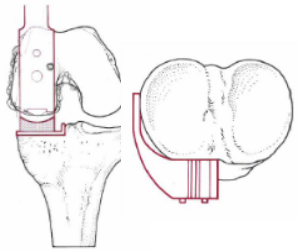

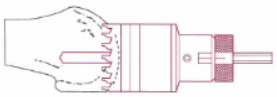

- Introduction of milling
- Improving reproducibility

Phase 3
1998 - 2011

- Improving milling technique
- Continued focus on reproducibility

Microplasty
2011 – Present…

- Focus on reproducibility

Instrumentation: Set Overview
Tibia 1

Top Tray

- Tibial Templates and Trials
- Nails, drill bits, puller

Bottom Tray

- Tibial Impactor, Inserter
- Tibial Groove Cutters
- Slap Hammer
- T-Handle
- Bearing Inserter/Extractor



Instrumentation: Set Overview
Tibia 2

Top Tray

- Tibial Resection
- IM Link
- IM Rod Pusher

Bottom Tray

- IM Rods
- Anterior Mill
- Impactor
- Spigots
- Toffee Hammer
- Drills
- Bone Collar Remover
- 5mm Awl





Instrumentation: Set Overview
Size Specific

Specific for Femoral Size

- Femoral Trials
- Bearing Trials
- Femoral Drill Guide
- Femoral Resection Guide
- Anti-Impingement Guide
- Feeler Gauges
- Mill

Overview of Size Specific Trays



XSM



SM



MD



LG



XLG

ZIMMER BIOMET

Surgical steps

highlights of Oxford Microplasty

Oxford Microplasty

- Design Goal: Simple, Easy, Accurate, Reproducible
- No change in indications
- Enhancement in tibial resection instruments
- IM linked femoral preparation
- Anti-impingement instrumentation
- Trial bearing inserts by hand

Indications/Contraindications

Indications

- Antero-medial OA
- Intact ACL
- Full Thickness Lateral
- Correctable Varus
- Fixed Flexion Deformity (FFD) less than 15°

1 in 4 OA Knees!

Not Contraindication

- Patello-femoral Joint
- Obesity
- Age
- Activity

Tibial Preparation

Goals

- Minimize resection depth
- Maximize surface area
- Decrease re-cutting
  - Offers shims for recutting in +/- 2mm increments
- Appropriate slope

Tibial Preparation

- Tibial Slope
  - Parallel to tibial crest
  - 7 degrees
- New ankle positioning
  - Helps avoid overslope
- Pinned to tibia
  - Single nail suffices

Tibial Preparation

- Sizing spoon placed under posterior medial femoral condyle
- 1,2,3 mm spoons (1mm spoon is default)
- Ligament tension achieved
- Clamped to tibial guide with G-Clamp

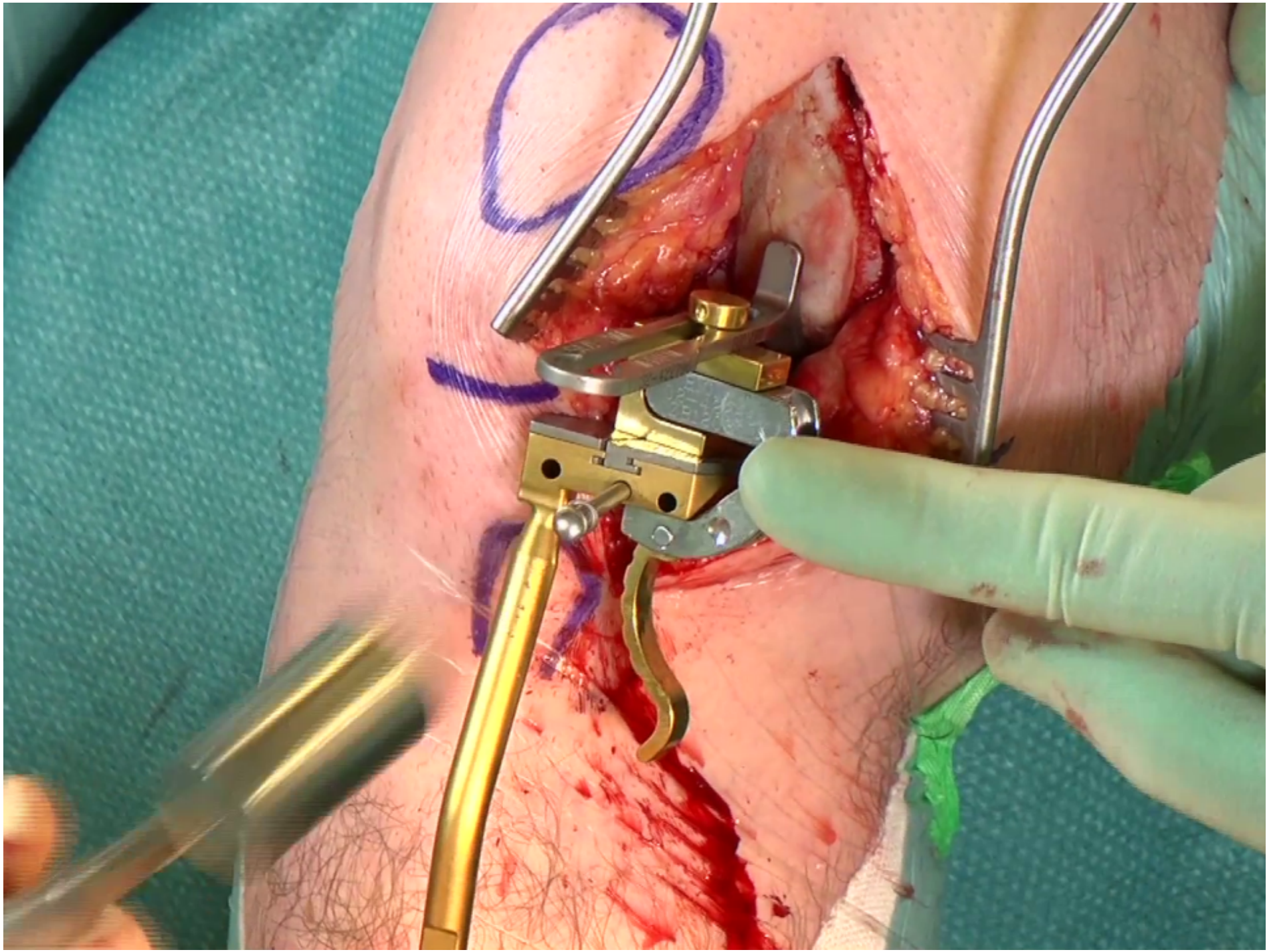

Tibial Preparation

- Vertical cut important
- M/L position
  - Adjacent to ACL footprint
- Rotational position
  - ASIS/Flexion plane
- Depth
  - DON’T LIFT HAND

Tibial Preparation

- "Curly Whirly" inserted
  - Protect the MCL
- Flat cut
- Slotted guide available
- Shim option
  - Additional 2mm

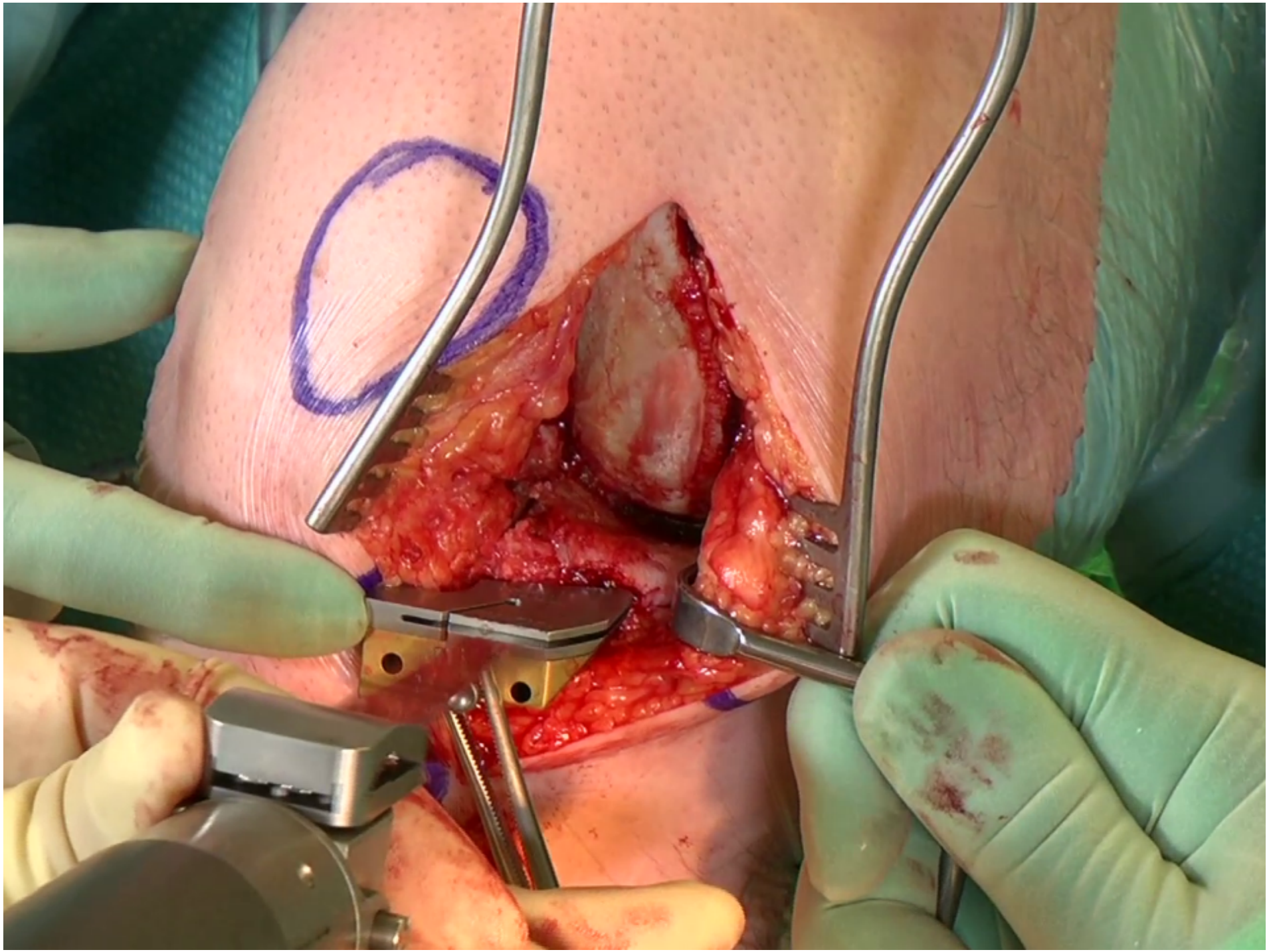

Femoral Preparation

- IM rod cannulated
  - Flexion/extension
  - Varus / valgus
- Starting position critical
- Yellow pusher
- Mark central third

Femoral Preparation

- Femoral drill guide set
- Inserted and linked
- Position of link important
- Must be seated
- M/L position confirmed

Femoral Preparation

- "Flat arm" of link in IM hole
- Curved arm in femoral drill guide
- Foot of guide against tibial resection
  - In contact with femur
- Central third confirmed
- Correct hole, not femoral drill
  - Link out of way of drill hole
  - Places drill holes 10° flexed, and 7° valgus

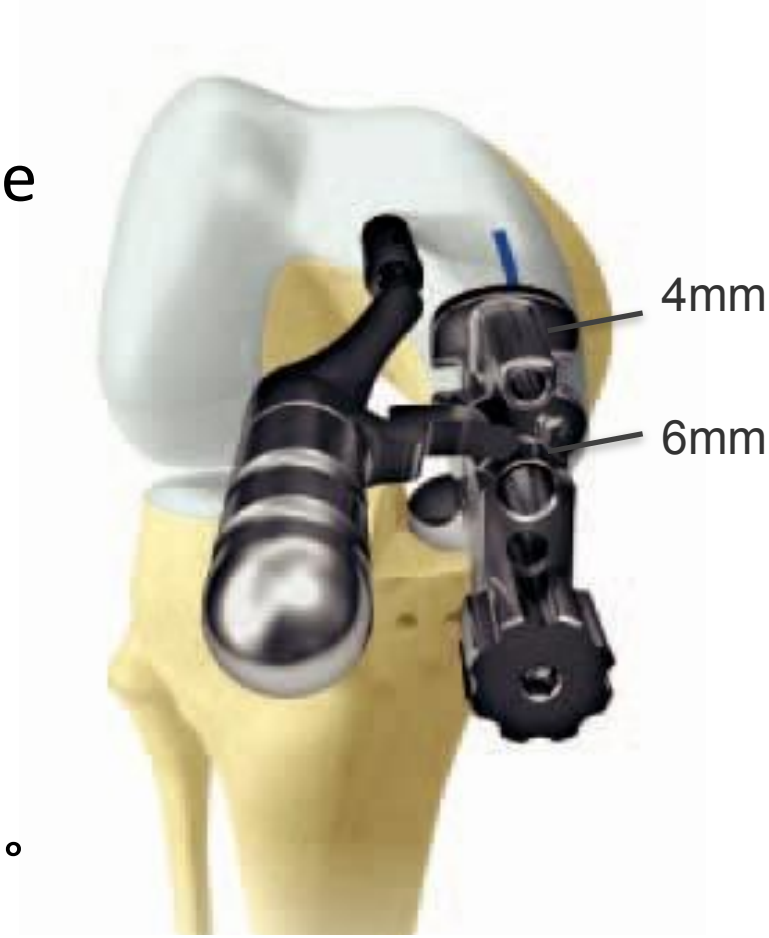

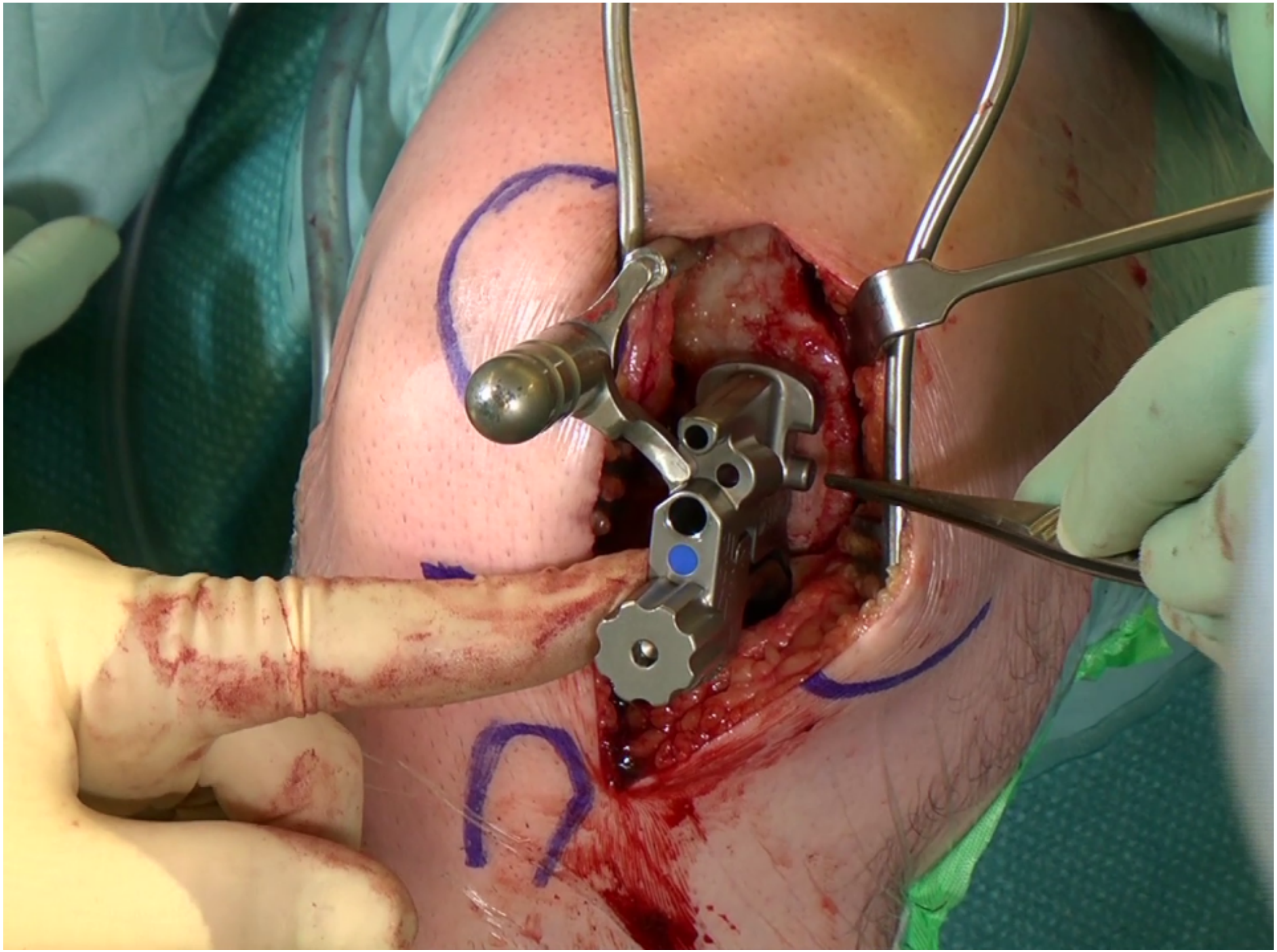

Femoral Preparation

- New curved slotted posterior cutting guide
- Suitable for Oxford oscillating sawblade
- Allows blade to be flexed and for saw throw
- Goal: to prevent over/ under resection

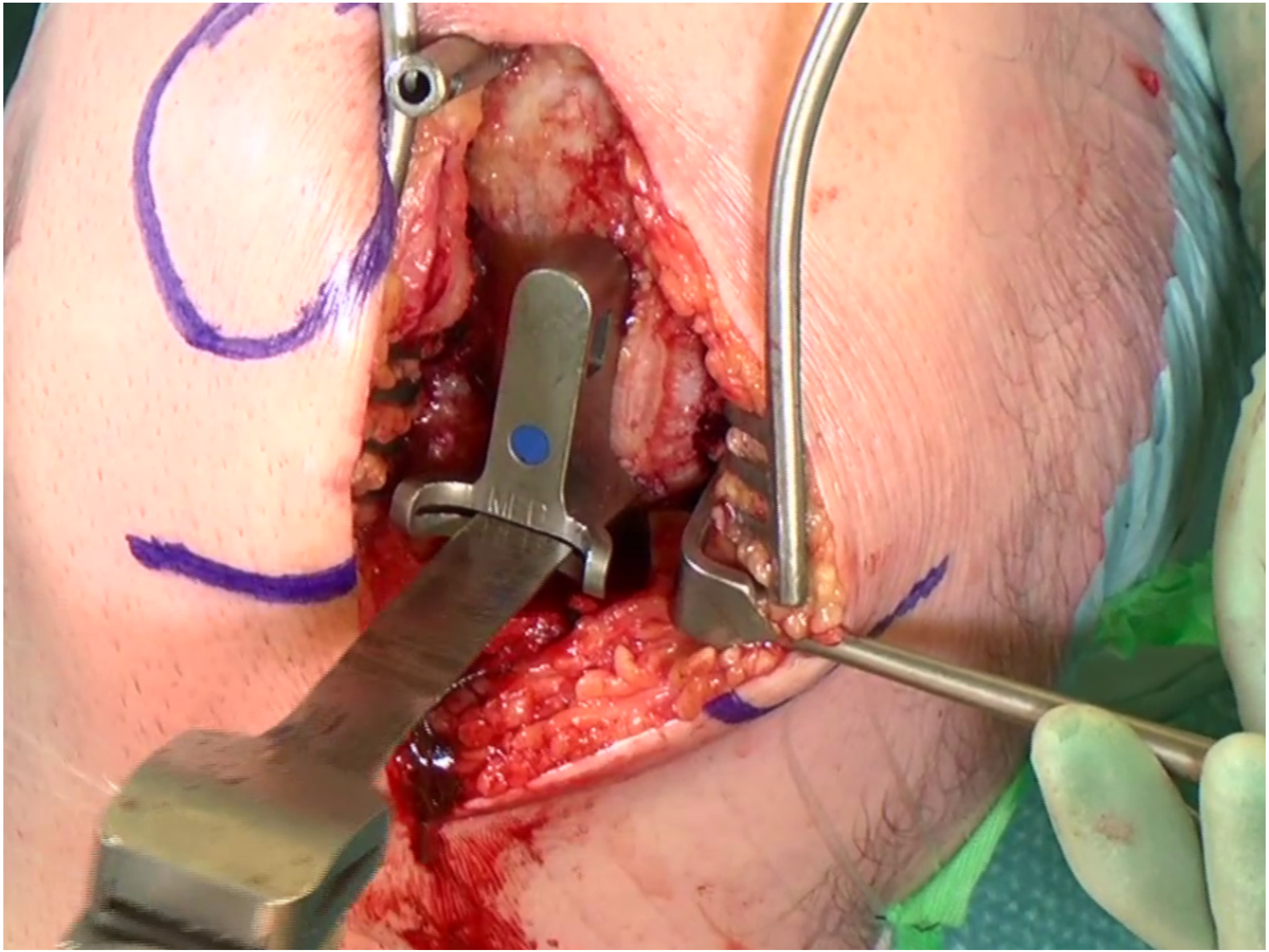

Femoral Preparation

- Milling
  - Curve off femur with 0 spigot

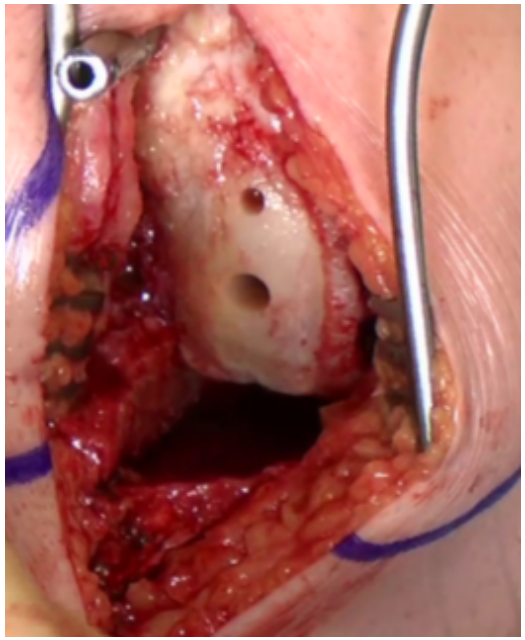
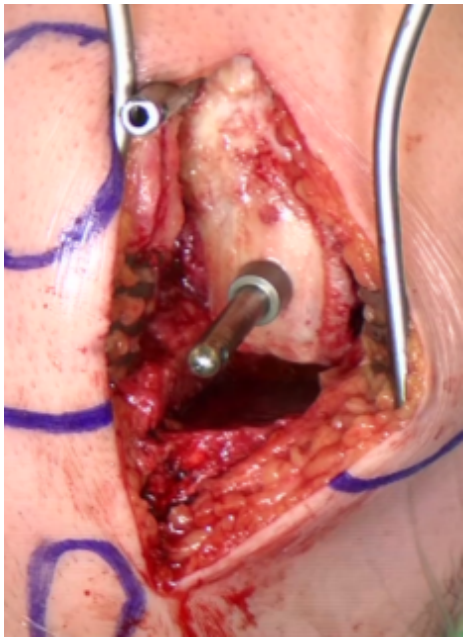
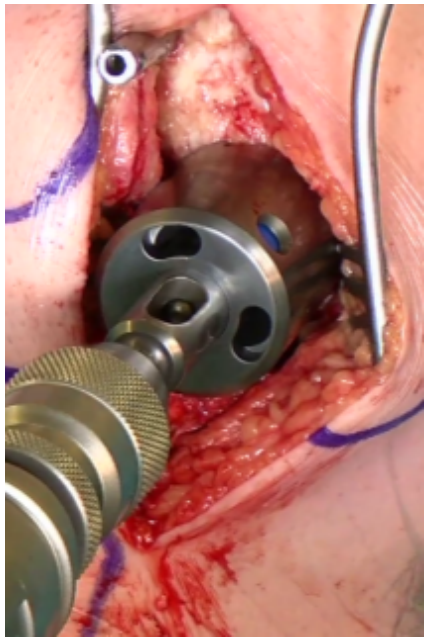
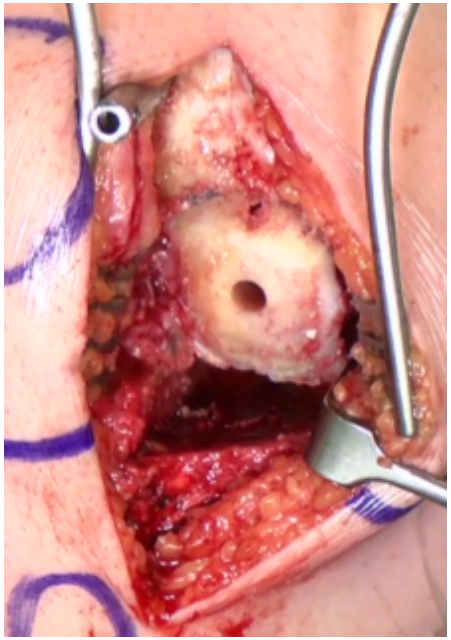

Gap Assessment

- Use single peg femoral trial to balance
- New tapered feeler gauges
- Less soft tissues interference
- Gaps determined
- Standard milling to balance
- 1,2,3 mm plastic feeler gauges

Anti-Impingement

- Decreases early and late complications
- Replaces traditional “Freehand technique”
- New instruments help guide bone removal

Anti-Impingement

- Anterior mill
- Size specific
- Similar to a calcar reamer
- Spring loaded plunger
- Extend the knee
- <u>Care to watch tibia…</u>

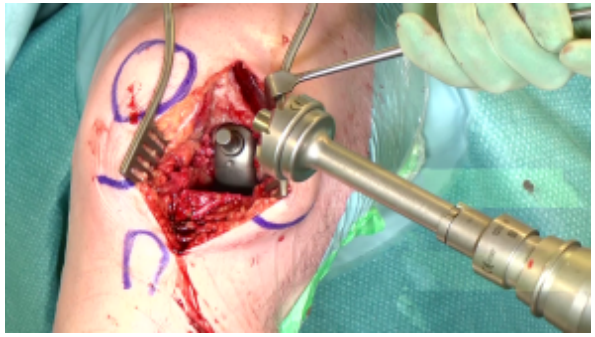

Final Trialing

- Insert tibial tray trial and single peg femoral trial
- Trial bearing inserted by hand
- Better “feel” of tension
- Assess tracking
- Check impingement

Trial Bearing Removal

ZIMMER BIOMET

Cementing the Components

- Cementing technique follows current Phase 3 Oxford Knee surgical technique
- Two staged
  1. Tibia
     - Small amount on tibia
     - Use tibial impactor
     - Compress at 45 deg with trial femur
  2. Femur
     - Cement into large hole
     - Concave surface of femoral component
     - Impact at 45 deg to the long axis
     - Compress at 45 deg with feeler gauge

ZIMMER BIOMET

Cementless

Differences vs Cemented

Keel Preparation

Use cementless tooth brush saw through tibial template

Cemented

Use cemented tibial groove cutter

Cementless

Option to use the cementless tibial groove cutter

Implant

- Use cementless tibial inserter
- Two insertion tabs on cementless tibia
- Bring in at an angle, and lightly tap home



ZIMMER BIOMET

Conclusion

Oxford Microplasty

Proven to deliver more accurate and reproducible results

- 219 Ph3 v 196 OXMP
- Concluded that OXMP delivered:
  - A more accurate alignment of the femoral implants
  - A more accurate alignment of the tibial implants
  - A more accurate resection, with a greater number of thinner 3mm and 4mm bearings

ARTICLE IN PRESS

The Journal of Arthroplasty xxx(2014) xxx–xxx

Contents lists available at ScienceDirect

The Journal of Arthroplasty

journal homepage: www.arthroplastyjournal.org

Radiographic Comparison of Mobile-Bearing Partial Knee Single-Peg Versus Twin-Peg Design

Jason M. Hurst, MD [a], Keith R. Berend, MD [a,b,c], Joanne B. Adams, BFA [a], Adolph V. Lombardi Jr., MD, FACS [a,b,c]

[a] Joint Implant Surgeons, Inc., New Albany, Ohio
[b] Department of Orthopaedics, The Ohio State University Wexner Medical Center, Columbus, Ohio
[c] Mount Carmel Health System, New Albany, Ohio

ARTICLE INFO

Article history:
Received 25 July 2014
Accepted 10 October 2014
Available online xxxx

Keywords:
unicompartmental knee arthroplasty
partial knee arthroplasty
component design
radiographic analysis
surgical technique
instrumentation

ABSTRACT

The femoral component and proprietary instrumentation of a mobile-bearing unicompartmental knee arthroplasty (UKA) was redesigned with an additional peg for enhanced fixation, 15° of extra femoral surface for contact in deep flexion, more rounded profile, better fit into the milled surface, and redesigned intramedullary based instrumentation. To assess the benefit of these changes, we compared postoperative radiographs of 219 single-peg and 186 twin-peg UKAs done in 2008–2011. All surviving knees demonstrated satisfactory position and alignment with no radiolucencies observed. Radiographic analysis showed improved and consistent component positioning with the twin-peg design implanted with updated instrumentation compared with the single-peg. The radiographic benefits of improved implant positioning using the twin-peg component and updated instrumentation are clear and carry tremendous potential. More robust follow-up is imperative.

Numerous studies have reported favorable results with a medial-mobile bearing unicompartmental partial knee arthroplasty design [1–13]. The most recent modifications to the mobile-bearing Oxford Partial Knee (Biomet, Warsaw, IN) were intended to improve the process of implantation and the reproducibility of implant positioning, and enhance the stability and mechanics of the femoral component. In an attempt to improve the reproducibility of implant positioning, an intramedullary based femoral preparation guide (Fig. 2A and B) and anti-impingement guide (Fig. 2C) were developed (Microplasty Instrumentation; Biomet). This new instrumentation was specifically designed to incorporate the newly modified femoral component. The femoral component was redesigned with an additional peg for more secure fixation and 15° of extra femoral surface for contact in deep flexion. Further design modifications have been made to the twin-peg to enhance kinematics and durability, including a more rounded profile, better fit into the milled surface, and 7° of extra femoral surface (Fig. 1B). To assess the benefit of these instrumentation and design changes, we compared the postoperative radiographs and implantation related complications of the single-peg design (Fig. 1A) with the enhanced twin-peg design (Fig. 1B) implanted with the updated instrumentation.

Materials and Methods

A query of our practice's arthroplasty registry revealed 359 patients (413 knees) who signed an IRB-approved general research consent allowing retrospective review, and underwent medial unicompartmental knee arthroplasty performed with a mobile-bearing device between August 2008 and December 2011. Use of the enhanced twin-peg and updated instrumentation commenced in July 2011. One hundred eighty-eight patients (223 knees) received the single-peg design, and 171 (190 knees) received the enhanced twin-peg (Table 1). The preoperative diagnosis was avascular necrosis in 1 knee (enhanced twin-peg group) and osteoarthritis in all others. The groups were well matched in terms of gender, age, body mass index, preoperative ROM, and Knee Society pain and clinical scores. Forty-seven percent of patients were males (n = 187) and 53% were females (n = 192). Mean patient age at surgery was 63.5 years overall (SD 9.0; range 29–88 years), mean BMI was 32.2 kg/m² (SD 6.6, range 17–57 kg/m²), and mean ROM was 115.8° (SD 10.2, range 20°–135°). Patients in the single-peg group had slightly higher preoperative Knee Society function scores (61.4 versus 57.3; 0–100 possible).

Radiographs of adequate quality for review were available for 219 single-peg and 186 enhanced twin-peg knees. Immediate anteroposterior (AP) and lateral postoperative radiographs were assessed by a single observer (JMH) according to criteria described in the manufacturer's surgical technique guide (Oxford Partial Knee Microplasty Instrumentation Surgical Technique). Figs. 3 and 4 depict these criteria and measurements, and are as follows: position and size of the femoral component relative to the femur with varus/valgus angle < 10° varus to < 10° valgus (Fig. 3 criteria A), flexion/extension angle within 15° flexion to 0° extension (Fig. 4 criteria B), medial/lateral placement central (Fig. 3 criteria C),

Institutional research funding in direct support of this study was received from Biomet, Inc. Consulting fees, royalty payments, speaker's bureau payments, and research support received from Biomet, Inc.; royalty payment received from Innomed, Inc.; research support received from Stryker, Kinamed and Pacira.

The Conflict of Interest statement associated with this article can be found at http://dx.doi.org/10.1016/j.arth.2014.10.015.

Reprint requests: Jason M. Hurst, MD, Joint Implant Surgeons, Inc., 7277 Smith's Mill Road, Suite 200, New Albany, OH 43054

http://dx.doi.org/10.1016/j.arth.2014.10.015
0883-5403/© 2014 Elsevier Inc. All rights reserved.

Support Materials

Currently available on myBiomet

- Cementless Microplasty surgical video
- Cemented Microplasty surgical video
- Printed and digital surgical technique for Cementless and Cemented Microplasty
- Cemented Microplasty surgical technique animation
- Phase 3 vs Microplasty instrumentation animation

Summary

- Oxford Microplasty Instruments enhance
  - Tibial prep, resection depth (femoral size)
  - Femoral prep, component alignment precision
  - Impingement avoidance
- Oxford Microplasty Instruments are more accurate with less outliers than Phase 3 instrumentation

Disclaimer

Zimmer and Biomet do not practice medicine and do not recommend any particular orthopaedic implant or surgical technique and is not responsible for use on a specific patient. The surgeon who performs any implant procedure is responsible for determining and utilizing the appropriate techniques for implanting prosthesis in each individual patient.

ZIMMER BIOMET

Your progress. Our promise.™